



Cardiology Consultation Report Electrocardiographic Interpretation

Date: Tuesday, October 19, 1999

Clinic: 5223

Report: 37-648

Veterinarian: Dr. Bossart

Client: Riccardi

Breed: Great Dane

Clinic: Animal Hospital of Ft. Lauderdale

Pet: Lady

Age: 8.5 yr

Phone: 954-551-8777

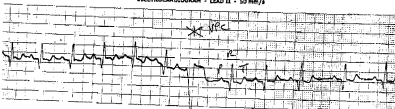
Species: Canine

Sex: F-S

FAX: 954-551-0944

Wt: 140 lb

ELECTROCARDIOGRAM - LEAD II - 50 mm/s



BURDICK P/N 007949

HEART RATE: 120-168 Rhythm: NSA-RSR/VPC

Veterinary Heart Institute

3501-W 5W 2nd Avenue • Gainesville, FL 32607
889-344-1019 • 352-371-7900 • 352-371-7910 (FAX) • <http://www.vhi-texas.com>



Cardiology Consultation Report Electrocardiographic Interpretation

Date: Tuesday, October 19, 1999

Clinic: 8223

Report: 37-848

Veterinarian: Dr. Bossart

Client: Riccard

Breed: Great Dane

Clinic: Animal Hospital of Ft. Lauderdale

Pet: Lady

Age: 6.5 yr

Phone: 954-561-8777

Species: Canine

Sex: F-B

FAX: 954-561-0944

Wt: 140 lb

Chief Complaints/Clinical Signs: There is a history of discomfort last night. Radiographs of the shoulder were planned today. Physical examination demonstrated no cardiac murmur.

Laboratory Findings: Pending

Radiographic Findings: Thoracic radiographs performed 1 month ago were within normal limits.

Current Medications: N/A

ECG Findings

Heart Rate: 120-188

Rhythm: NSR-RSRVPC

P-QRS-T: WNL

MEA: 50 degrees

ECG and Clinical Assessment: Lady's electrocardiogram today demonstrates a normal sinus arrhythmia to rapid sinus rhythm at a rate of 120-188 beats per minute. Occasional ventricular premature complexes are noted. The waveforms are within normal limits. As we discussed, dilated cardiomyopathy is a concern in this breed. Occasionally ventricular premature complexes without systolic dysfunction can be seen as an early indicator of dilated cardiomyopathy. Myocarditis (idiopathic or rickettsial) or non-cardiac disease such as neoplasia can also result in the arrhythmia noted. Further diagnostic tests are needed.

Recommendations:

- Laboratory:** If there is evidence of rickettsial disease (history of ticks, thrombocytopenia or anemia), rickettsial titers would be warranted.
- Procedures:** Recheck thoracic radiographs should be considered. An echocardiogram would be ideal. A Holter monitor may also be warranted to assess for the presence of ventricular tachycardia or more severe arrhythmias in a 24-hour period.
- Therapy:** Specific therapy can be decided pending results of tests. Antiarrhythmic therapy will likely be needed.
- Diet:** A standard diet may be provided.
- Exercise Allowed:** Restricted at this time.
- Recheck Evaluation:** Based on findings of tests.
- Comments:** Please call with findings of your pending tests to discuss appropriate therapy. If there are any questions regarding this or any other cases, please give me a call.

Darin J. Borda, DVM, Cardiology Resident

Veterinary Heart Institute

3601 W SW 2nd Avenue • Gainesville, FL 32607
888.814.7019 • 352.371-7900 • 352.371-7910 FAX • <http://www.veheart.com>